

# Adverse effects of homeopathy: a systematic review of published case reports and case series

P. Posadzki, A. Alotaibi, E. Ernst

Posted by **Geoff Bond**  
Nutritional Anthropologist  
[www.naturaleater.com](http://www.naturaleater.com)

Complementary Medicine,  
Peninsula Medical School,  
Exeter, UK

**Correspondence to:**  
Paul Posadzki,  
Complementary Medicine,  
Peninsula Medical School,  
Veysey Building, Exeter EX2  
4SG, UK  
Tel.: +44 (0)1392 726043  
Fax: +44 (0)1392 421009  
Email: paul.posadzki@pcmd.ac.uk

**Disclosure**  
None.

## SUMMARY

**Aim:** The aim of this systematic review was to critically evaluate the evidence regarding the adverse effects (AEs) of homeopathy. **Method:** Five electronic databases were searched to identify all relevant case reports and case series. **Results:** In total, 38 primary reports met our inclusion criteria. Of those, 30 pertained to direct AEs of homeopathic remedies; and eight were related to AEs caused by the substitution of conventional medicine with homeopathy. The total number of patients who experienced AEs of homeopathy amounted to 1159. Overall, AEs ranged from mild-to-severe and included four fatalities. The most common AEs were allergic reactions and intoxications. *Rhus toxicodendron* was the most frequently implicated homeopathic remedy. **Conclusion:** Homeopathy has the potential to harm patients and consumers in both direct and indirect ways. Clinicians should be aware of its risks and advise their patients accordingly.

### Review criteria

We included all case reports and case series of homeopathic remedies to treat human patients suffering from any type of clinical condition using 5 databases from their inception to January 2012, without language restrictions.

### Message for the clinic

Homeopathy is one of the most commonly used type of complementary medicine. It is utilized for a wide variety of clinical conditions. Its safety has not been critically evaluated so far. The current evidence shows that homeopathy is not as innocent as it seems. It sometimes can lead to serious adverse events.

## Introduction

Homeopathy can be defined as 'a therapeutic method that often uses highly diluted preparations of substances whose effects when administered to healthy subjects correspond to the manifestation of the disorder (symptoms, clinical signs and pathological states) in the unwell patient' (1). It is one of the most popular form of complementary and alternative medicine in the UK and elsewhere (2). The reasons for this widespread use are probably complex, but the assumption that homeopathy is safe is certainly an important factor (1).

Although most homeopathic remedies are highly diluted, direct adverse effects (AEs) have been reported (3). Indirect risks mainly relate to replacing effective conventional treatments with ineffective homeopathic preparations (3,4).

The aim of this systematic review was to provide a summary and critical evaluation of the published evidence regarding direct and indirect AEs associated with homeopathy.

## Method

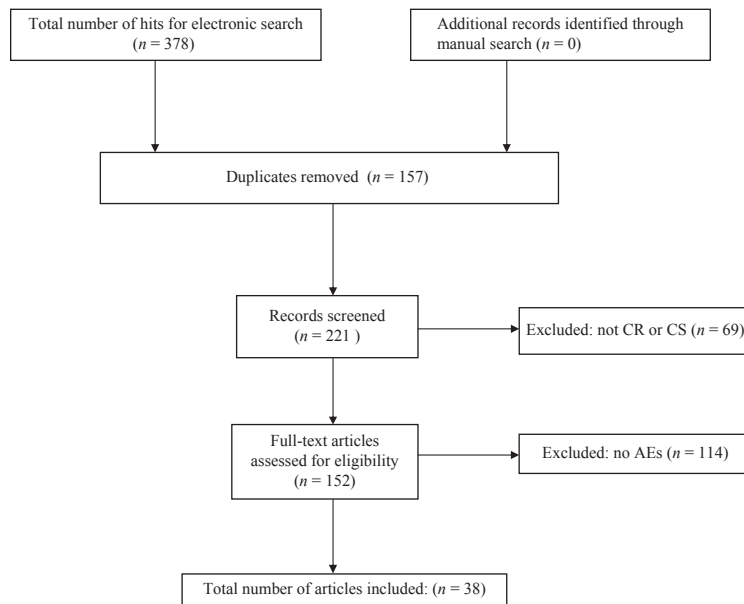
Electronic literature searches were conducted in January 2012 to identify case series (CS) and case reports (CR) of AEs associated with homeopathy in human

patients. The following electronic databases were used: MEDLINE, EMBASE, AMED, CINHAL and ISI. Details of the search strategy are presented in the Appendix. In addition, our own extensive department files were hand-searched for further articles.

No restrictions of language or time of publication were imposed. To be included, CS or CR had to pertain to AEs associated with the use of any type of homeopathic treatment in human patients. Data from spontaneous reporting systems were included as well. We also included reports where harm was not because of a homeopathic remedy, but was associated with the use of homeopathy as a replacement of conventional treatments. Information from the included CS or CRs were extracted according to predefined criteria and assessed by two independent reviewers. Causality was estimated based on the description provided by the authors of the primary articles. Any disagreements were settled through discussion.

## Results

Our searches generated 378 articles, of which 340 had to be excluded (Figure 1). Thus, 35 reports met our eligibility criteria (5–40). Table 1 summarises direct AEs associated with the use of homeopathy. Table 2 presents indirect AEs related to the substitution of conventional care with homeopathy.



**Figure 1** Flow diagram

The total number of patients amounted to 1159 (of those 1142 AEs were classified as direct and 17 as indirect AEs). The included articles originated from Austria, (5) Belgium, (20,31) Brazil, (16) Denmark, (23) France, (10,13,15) Germany, (36,38,40) Holland, (37) India, (32) Ireland, (18) Israel, (9,17,26) Italy, (11) Mexico, (29) Spain, (6,8,33) Sweden, (19) Switzerland, (25,39) UK (21,28) and the US (14,22,24). They were published between 1978 and 2010.

The implicated homeopathic remedies included Aconitum 1000, AKO-PLEX, Arsenic Bromide 1-X, *Arsenicum Sulfuratum Flavum-1-X*, *Baryta carbonica*, BHI Regeneration Tablets, *calcium carbonicum*, *Cantharis 1000*, caesium chloride, chromium, Forte Saponaria, *Gambogia*, Gali-col Baby, *hypericum perforatum*, Ipecacuanha, iron, *Kalium Bichromicum*, *Ledum Palustre*, *Lilium Compositum*, Loco X112, *Lycopodium*, *Malaria Officinalis*, Mercurius Heel®S, Mercurius 6a, *Mercurius Sublimatus Corrosivus*, Nat Mur 200, Notakehl, *Nux Vomica*, OT-10 and *Penicillium Chrysogenum*, *Pentackan Sinnabaum*, Petroleum D-5, Peruvian bark, *Pulsatilla*, *Rhododendron Ferrugineum*, *Rhus Toxicodendron*, *Ruta Graveolens*, Sedativ PC, Slenderness Drops, *Solanum Compositum*, sulphur, tanacetum, thuja, *tuberculinum* or unspecified homeopathic remedies.

Direct AEs included abdominal pain, flatulence, acute erythroderma, acute pancreatitis, severe allergic reactions, atopic dermatitis, burning lips, nausea, emesis, apnoea, cyanosis, regurgitation, anaphylaxis, arsenical keratosis and cancer, bladder cancer, bullous pemphigoid, severe asthenia, cardiac arrest, cognitive-behavioural disorders, coma, death, dermatitis, severe pulmonary involvement, emesis, euphoria,

extreme agitation, hyponatraemia and hypoalbuminaemia, erythaema, limb oedema, irritability and albuminuria, melanosis and keratosis, skin lesions, acute gastrointestinal illness, leukopaemia, thrombocytopaenia, diffuse dermal melanosis, metabolic acidosis, weight loss, chronic diarrhoea, morbiliform and pruritic rash with hospital admission, multiple alopecia and hair loss, pain, pancreatitis, problem with balance, somnolence, pruritus, swelling and erythroderma, renal failure with metabolic acidosis, interstitial nephritis and hyperkalaemia, severe acute tubulointerstitial nephritis, severe bradycardia, reversible conduction defect, hypotension and syncope, severe swelling, bleeding, rashes, sneezing, rhinitis, slight lethargy, symptoms of thall poisoning, tachypnea, high fever, lower limb areflexia, hypotension, pupillary abnormalities, gait ataxia, widespread leukocytosis and widespread maculopapular vesicular rash. Direct AEs of homeopathy occasionally resulted in serious outcomes including cancer, death, dialysis, toxic polyneuropathy and quadriplegia. In several instances, patients presenting AEs required hospital admission (7,14,18,19,24) and pharmacotherapy (5,18,29,35,36).

Indirect AEs included deterioration of pulmonary allergy, deterioration of sarcoidosis glomerulonephritis, hypertensive heart failure and encephalopathy, haemophilus influenzae meningitis, septicaemia high fever and seizures, malignant melanoma, multiple organ system failure, oedema, pneumococcal pneumonia with purulent pericarditis and coma, sepsis and death and severe aggravation of atopic dermatitis. Indirect AEs of homeopathy resulted in the following clinical outcomes: death, permanent hyper-

**Table 1** Case series and case reports of AEs directly related to homeopathy

Author (year) (Reference)	Study design	Number of patients	Homeopathic remedy (potency)	Concomitant treatment	Adverse event	Possible explanation	Causality	Treatment/clinical outcome
Aberer (1991) (5)	Case series	3	C.1. Peruvian bark and Ipecacuanha (D4) C.2. Unspecified slenderness drops (n.m.) C.3. Unspecified mixture of grass pollen (n.m.)	n.m.	C.1. Pruritus, swelling and erythroderma C.2. Morbilliform and pruritic rash C.3. Anaphylaxis	Allergic reactions*	Almost certain	C1 – Anti-histamines. NFI. C2 – Hospital admission. NFI C3 – ICU admission. Adrenaline, steroids and intravenous fluid supplementation. NFI
Audicana (2001) (6)	Case report	1	Mercurius Heel®S containing <i>Mercurius solubilis Hahnemannii</i> (D10), <i>Hepar sulfuris</i> (D8), <i>Lachesis</i> (D12), <i>Phytolacca</i> (D4), <i>Ailanthus glandulosa</i> (D3), <i>Echinacea angustifolia</i> (D3), <i>Belladonna</i> (D4)	Merbromin	Widespread maculopapular vesicular rash	Allergic reaction/mercury intoxication*	Almost certain	Systemic corticosteroids and antihistamines Post-inflammatory hypopigmentation remained
Aviner (2010) (7)	Case series	11	Gali-col Baby containing <i>Phosphorica</i> , <i>bryonia</i> , <i>Nux-vomica</i> , <i>Cuprum metallicum</i> and <i>Veratrum album</i> (n.m.)	n.m.	ALTE including apnoea, cyanosis, regurgitation, flaccidity or vomiting	Overdosing, toxicity*	Almost certain	Hospital admission. Lumbar puncture, lactate, ammonia, ECG, EEG, brain sonography, gastrografin imaging, and echocardiogram. All fully recovered within 13 days
Barquero, Romero (2004) (8)	Case report	1	<i>Nux vomica</i> and <i>Rhus tox</i> (n.m.)	Glimepiride	Acute pancreatitis, necrosis of the pancreatic head	Unclear†	Likely	ICU admission. Respiratory distress, gastrointestinal bleeding and death after 2 weeks Full recovery
Berneiz (2008) (10)	Case report	1	Sedativ PC (6 ingredients in 6CH)	n.m.	DRESS syndrome, severe pulmonary involvement	Hypersensitivity*	Certain	Full recovery
Cardinali (2004) (11)	Case report	1	1. <i>Rhus Toxicodendron</i> mother tincture (alcohol solution) 2. <i>Rhus Toxicodendron</i> (7CH)	n.m.	Widespread dermatitis, leukocytosis	Allergic reaction*	Certain	Full recovery
Chakraborti (2003) (12)	Case series	3	C.1. & C.3. Arsenic Bromide 1-X (n.m.) C.2. <i>Arsenicum Sulfuratum Flavum</i> -1-X (n.m.)	n.m.	C.1. Melanosis and keratosis, C.2. Skin lesions C.3. Acute gastrointestinal illness, leukopaenia, thrombocytopaenia and diffuse dermal melanosis	Arsenic intoxication*	Almost certain	C1-C2 – Improvement on discontinuation C3 – Toxic polyneuropathy and quadriparesis

Table 1 Continued

Author (year) (Reference)	Study design	Number of patients	Homeopathic remedy (potency)	Concomitant treatment	Adverse event	Possible explanation	Causality	Treatment/clinical outcome
Curry (2006) (14)	Case report	1	Caesium chloride (n.m.)	Chemotherapy, anaesthetic agents, CoQ10, coral calcium, bovine colostrum, seal oil, multivitamin, vitamin D, n.m.	Cardiac arrest	Cesium intoxication* or interactions with anaesthetic agents†	Likely	Full recovery. NFI
Duque-Estrada (2009) (16)	Case series	1	Injection of <i>Lilium compositum</i> , <i>Solanum compositum</i> , <i>Thuja</i> , and <i>Tanacetum</i> (n.m.)		Hair loss	Unclear*	Almost certain	Complete recovery after 7 months
Farrell (1995) (18)	Case report	1	Oral <i>Hypericum perforatum</i> and <i>Ledum palustre</i> (n.m.)	None	Severe acute tubulointerstitial nephritis	Unclear†	Likely	Hospital admission. Hemodialysis and methylprednisone. Improved renal function after 14 days
Forsman (1991) (19)	Case series	2	C.1. a. AKO-PLEX containing: <i>Juglans</i> (D6), <i>Silicea</i> (D12), <i>Antimonium</i> (D12), <i>Arnica</i> (D6), <i>Sarsaparilla</i> (D6), <i>Daisies</i> (D6), <i>Mezereum</i> (D6), <i>Dulcamara</i> (D6) b. Forte Saponaria containing: <i>Gramin jugul.</i> , <i>Rhamnus cath.</i> , <i>Viola od.</i> , <i>Cichor.</i> , <i>Cent.</i> , <i>Inula</i> , <i>Nastur.</i> , <i>Sapon.</i> , <i>Scroph. Bellis</i> , <i>Viola tr.</i> , <i>Dulcam.</i> , <i>Hydrocot.</i> , <i>Mezer.</i> , <i>Sarsap.</i> , <i>Thuja</i> (all at D6) c. OT 10 containing: <i>Sennae</i> , <i>Fragula</i> , <i>Phaseoli</i> , <i>Mentha pip.</i> , <i>Rubi</i> , <i>Fucus</i> , <i>Maliuae</i> , <i>Taraxacum</i> , <i>Betula alba</i> C.2. Three different unspecified preparations (n.m.)	n.m.	C.1. Atopic dermatitis C.2. Severe swelling, bleeding and rashes	Allergic reaction*	Likely in both cases	C1 – Hospital admission. Topical steroids and antihistamines. Full recovery within several months. C2 – Hospital admission. NFI

Table 1 Continued

Author (year) (Reference)	Study design	Number of patients	Homeopathic remedy (potency)	Concomitant treatment	Adverse event	Possible explanation	Causality	Treatment/clinical outcome
Geukens (2001)(20)	Case report	1	<i>Aconitum 1000</i> , <i>Baryta carbonica</i> , <i>Cantharis 1000</i> , <i>Gambogia</i> , <i>Pulsatilla</i> , <i>Rhus tox</i> (M and 10 M)	n.m.	Heart disease and bladder cancer	Unclear†	Almost certain	Radiotherapy. Full recovery
Goodyear (1990) (21)	Case report	1	Nine different remedies, including iron and arsenic (both at 6 °C)	n.m.	Hyponatraemia, hypoalbuminaemia, erythaema and limb oedema	Unclear*	Almost certain	Hospital admission. Sodium chloride solution, albumin infusions, intravenous flucloxacillin and benzylpenicillin, potassium permanganate baths, topical corticosteroids and antibiotics. Persistent mild eczema at 4 months follow up
Guha (1999) (22)	Case report	1	Tincture of aconite	n.m.	Severe bradycardia, reversible conduction defect, hypotension and syncope	Aconitum intoxication*	Almost certain	Marked improvement in symptoms within a few hours
Kerr (1986) (24)	Case report	1	Regeneration Tablets- a mixture of 19 ingredients (n.m.)	n.m.	Pancreatitis, pain, nausea, vomiting	Protoanemonin and saponin glycosides toxicity†	Almost certain	Hospital admission. Conservative treatment. Full recovery after 6 days
Kuenzli (2004) (25)	Case report	1	Topical and/or oral calcium, sulphur, <i>Lycopodium</i> , <i>Mercurius</i> , <i>Cantharis</i> , <i>Rhus toxicodendron</i> , <i>Calcium carbonicum</i> , <i>sepia</i> and <i>tuberculinum</i> (n.m.)	None	Bullous pemphigoid, severe asthmaemia	Mercury intoxication*	Likely	Oral prednisone and sulfapyridine. Rapid improvement within 2 weeks
Menniti-Ippolito (2008) (27)	Case series	21	Various remedies-both mono and poly-preparations, including <i>Kalium Bichromicum</i> and <i>Mercurius Sublimatus Corrosivus</i> (from D1)	n.m.	Allergic reactions	Immune allergic reactions, hypersensitivity†	Likely	n.r.
Monk (1986) (28)	Case report	1	Injection of Nat Mur 200 (n.m.)	n.m.	Acute erythroderma	Unknown*	Likely	ICU admission. n.r.
Montoya-Cabrera (1991) (29)	Case report	1	Mercurius 6a (D6)	n.m.	Dermatitis, irritability and albuminuria	Mercury intoxication*	Almost certain	D-penicillamine administration. Full recovery
Morteimans (2004) (30)	Case report	1	Loco X112 drops (n.m.)	Alcohol and amphetamine	Extreme agitation	Interactions of alcohol, thyroid extract free T3 and T4, diethylpropione, and amphetamine* and†	Likely	Diazepam, propofol. Full recovery

Table 1 Continued

Author (year) (Reference)	Study design	Number of patients	Homeopathic remedy (potency)	Concomitant treatment	Adverse event	Possible explanation	Causality	Treatment/clinical outcome
Potier (1998) (31)	Case report	1	Unspecified remedies (n.m.)	n.m. but patients with history of depression, cholecystectomy, neurological and vascular accidents.	Coma	Bromate intoxication*	Likely	Antibiotics, mucolytics and haemodialysis. Full recovery within 15 days
Prasad (2006) (32)	Case report	1	Unspecified remedy (n.m.)	n.m. but patient with a history of neck swelling, cough, haemoptysis, shortness of breath, fever and weight loss	Artenical keratosis and cancer	Arsenic intoxication*	Likely	Hospital admission. Death
Rodriguez-Vico (2009) (33)	Case report	1	Petroleum (D5)	Carbamazepine	Tachypnoea, high fever, lower limb areflexia, hypotension, pupillary abnormalities, gait ataxia, cognitive-behavioural disorders	Kerosene intoxication*	Almost certain	Hospital admission. Full recovery within 1-week
Sasseville (1995) (34)	Case series	2	C.1. Ointment containing <i>Rhus toxicodendron</i> (2CH), <i>Rhododendron ferrugineum</i> (2 CH), <i>Ruta graveolens</i> (2 CH), <i>Ledum palustre</i> (2 CH) C.2. Ointment containing <i>Rhus toxicodendron</i> tincture 4.00 g Unspecified remedy (n.m.)	History of dermatitis	Allergic dermatitis, perioral swelling and vesiculation	Allergic reactions*	Likely	C1 – Clobetasol 17-propionate. Full recovery within 2 weeks C2 – Oral corticosteroids. Full recovery within 5 days
Stevens (1978) (35)	Case report	1	Unspecified remedy (n.m.)	None	Migraine, retrosternal oppression, paresthesias, pain, burning sensation,	Thall intoxication*	Likely	Prussian blue and potassium chloride. Full recovery within 1-week
Turkoglu-Raach (2010) (36)	Case report	1	Notakehl® containing <i>Penicillium chrysogenum</i> (D4)	n.m.	Renal failure with metabolic acidosis, interstitial nephritis and hyperkalaemia	Allergic reaction* and†	Likely	Corticosteroids and hemodialysis. Full recovery
Van Ulsen (1988) (37)	Case report	1	Pentactan Sinnabaum (D4)	n.m.	Severe exacerbation of eczema with swelling	Chromium intoxication*	Likely	No improvement.
Von Mach (2006) (38)	Case series	1070	Unspecified remedies (n.m.)	n.m.	Mostly mild symptoms (no details provided)	Unclear*	Unclear	n.r.

Table 1 Continued

Author (year) (Reference)	Study design	Number of patients	Homeopathic remedy (potency)	Concomitant treatment	Adverse event	Possible explanation	Causality	Treatment/clinical outcome
Wille (2010) (39)	Case report	1	Xylitol containing homeopathic globules	n.m.	Severe metabolic acidosis, weight loss, chronic diarrhoea	Enteral bicarbonate loss*	Likely	ICU admission. Full recovery after 3 months
Zuzak (2010) (40)	Case series	9	C.1.–C.2. <i>Calendula officinalis</i> (mother tincture) C.3. <i>Mater perlarum</i> (D4) C.4. <i>Allium cepa</i> (D4–D15) C.5.–C.6. Chamomile globules (n.m.) C.7. Bach flower rescue drops (n.m.) C.8. Chamomilla (D10), Mercurius (D15), sulphur (D12) C.9. Thuja (mother tincture)	n.m.	C.1. Sneezing, rhinitis; C.2. Slight lethargy; C.3. Emesis; C.4. euphoria; C.5. Abdominal pain, flatulence; C.6. Emesis; C.7. Problem with balance, somnolence; C.8. Pain; C.9. Burning lips, nausea, emesis	Unclear*	Likely in all cases	n.r.

AEs, adverse effects; ALTE, apparent life-threatening event; DRESS, drug rash with eosinophilia and systemic symptoms; ECG, electrocardiogram; EEG, electroencephalogram; ICU, intensive care unit; NFI, no further information; n.r., not reported; SB, sinus bradycardia; TdP, torsades de pointes; VF, ventricular fibrillation; C, case.

\* As judged by the author of primary report.

† As judged by the present author.

**Table 2** Case series and case reports of AEs related to substitution of conventional care with homeopathy

Author (year) (Reference)	Study design	Number of patients	Homeopathic remedy (potency)	Concomitant treatment	Condition	Possible explanation	Causality	Treatment/clinical outcome
Benmeir (1991) (9)	Case report	1	Ointment and unspecified remedies (n.m.)	n.m.	Malignant melanoma	Negligence and lack of CT†, ‡	Certain	Surgery. Full recovery after 7 months
Collin (2006) (13)	Case series	2	<i>Lycopodium</i> , <i>Pulsatilla</i> and Sulphur*(CH 15 and 30)	n.m.	Deterioration of pulmonary allergy	Unclear‡	Likely	n.r.
Delaunay (2000)(15)	Case report	1	<i>Ledum palustre</i> (5CH) and <i>Malaria officinalis</i> (4 CH)	Conventional prophylactic drugs, NFI	Multiple organ system failure	Parasitaemia†	Certain	ICU admission. Intensive care for 2 months. NFI
Edelson (1999) (17)	Case report	1	Unspecified remedy (n.m.)	n.m.	Deterioration of sarcoidosis	Discontinuation of CT†	Almost certain	Hospital admission. Corticosteroids. NFI
Forsman (1991) (19)	Case report	1	Unspecified ointment	n.m.	Malignant melanoma	Delayed diagnosis‡	Likely	Unknown
Ibsen (1987) (23)	Case series	4	Unspecified remedies (n.m.)	n.m.	C.1.–C.4. Severe aggravation of atopic dermatitis	Discontinuation of CT‡	Likely	ICU admission. Full recovery
Lim (2011) (41)	Case series	3	Unspecified remedies (n.m.)	n.m.	C.1. Malnutrition, sepsis and death C.2. Malnutrition and oedema C.3. Seizures	Negligence and lack of CT†, ‡	Certain	Hospital admission. NFI
Luder (2000) (26)	Case series	3	Unspecified remedies (n.m.)	n.m.	C.1. Pneumococcal pneumonia with purulent pericarditis and coma C.2. Glomerulonephritis, hypertensive heart failure and encephalopathy C.3. <i>haemophilus influenzae</i> meningitis, septicaemia high fever and seizures	Negligence and lack of CT†, ‡	Certain	C.1. Death C.2. Permanent hypertension C.3. Hydrocephalus and neuro-surgical and drainage

AEs, adverse effects; ICU, intensive care unit; CT, conventional treatment; NFI, no further information; n.m., not mentioned; C, case.

\*The most commonly used.

†As judged by the author of primary report.

‡As judged by the present author.



tension, hydrocephalus and the need for neurosurgical drainage.

The duration of AEs ranged from a few hours (22) to 7 months (9,16). Eighteen patients experienced a full recovery (6,7,9–12,14,16,18,21–25,29–31,33,35,36,39) and four died (8,26,32,41). In six cases, details of AEs were insufficient for a judgment regarding cause and effect (13,19,27,28,34,37,38,40). In 17 cases, causality was deemed to be likely, certain in six, almost certain in 12 and unclear in one. The AEs were caused by allergic reactions, (5,6,8,11,19,27,34,36,39) ingestion of toxic substances (6,7,12,21,22,24,25,29–33,35,37) and substitution of conventional care (9,13,15,17,19,23,26,41).

## Discussion

Our systematic review was aimed at summarising and critically evaluating the available evidence from CS and CR regarding AEs of homeopathy in human patients. According to our findings, homeopathy can lead to AEs, some of which are serious. A recent report on the safety of homeopathy by the European Council for Classical Homeopathy (ECCH) concluded that homeopathy is 'safe to use'. However, this report was incomplete and included only a third of the CRs/CS located by us for the present review (42). The ECCH-report also commented on the safety of homeopathy relative to conventional treatments. It seems likely that homeopathic remedies cause far less and fewer AEs than conventional drugs, however, such a comparison might be misleading as not the absolute risk of an intervention, but its risk-benefit balance would determine the value of any medical treatment. If the benefit is small or non-existent, even a minute risk would tilt this balance into the negative.

An audit of the Bristol Homeopathic Hospital among 116 patients reported that 11% of them experienced AEs, including headaches, lethargy or vomiting (43). This percentage figure is difficult to interpret as the authors categorise diarrhoea, eczema, gastrointestinal upset, hair loss, infections, nausea, migraines, pains, rash, skin irritation, tension headaches, tiredness/fatigue as 'homeopathic aggravations', new symptoms and/or return of old symptoms. Our own review of the evidence for or against the existence of homeopathic aggravations included 24 placebo-controlled trials reporting aggravations, and we came to the conclusion that 'this systematic review does not provide clear evidence that homeopathic aggravations exist' (44).

In the majority of cases, the possible mechanism of action involved allergic reactions or ingestion of toxic substances. Preparations of heavy metals, such as arsenic, cadmium, mercury or iron, which are frequently used in homeopathy can be toxic, (45) if not

highly diluted. Other poisons regularly employed in homeopathy include aconitum, kerosene or thallium, which also can lead to serious health problems in sufficiently low dilutions.

We identified both direct and indirect AEs of homeopathy. The former related to the homeopathic remedy itself and the latter predominantly referred to the replacement of effective conventional therapies with ineffective homeopathic remedies. It was often impossible to distinguish precisely between the two types of AEs. The information whether a fully qualified and registered homeopath applied, the homeopathic remedy was frequently missing. Similarly, other valuable details were often not included in the primary publications. In 94.7% of cases, the potencies were described as below 12 °C, the point beyond which the likelihood of a single molecule being present in the remedy approaches zero. It is plausible that low dilutions of homeopathic preparations cause direct AEs, particularly allergic reactions. One might argue that incidences classified as indirect AEs by us are not truly AEs of homeopathy, but are the result of less than competent healthcare. We have therefore tried to differentiate as clearly as possible between the two. One might also wonder why relatively few indirect AEs have been reported. Most experts view the use of ineffective homeopathic treatments for serious conditions is potentially more harmful than the harm done by homeopathic remedies. One explanation could be that indirect harm of this nature rarely gets reported. Evidence of indirect AEs highlight the need for all homeopaths to be adequately trained such that harm of this nature can be avoided in future.

The preference of homeopathy over conventional medicine when dealing with serious, life-threatening conditions may cause serious harm, and this issue relates to the question of practitioner training (15,17,26). The treatment of cervical streptococcal lymphadenitis, acute lymphatic leukaemia, bacterial pneumonia and atopic dermatitis with homeopathic remedies is clearly dangerous (4,26,46) simply because homeopathy is not effective for any of these conditions. Other examples of serious conditions that have been treated homeopathically include anxiety, (47) depression, (48) eczema, (49) insomnia, (50) migraine prophylaxis and rheumatic conditions (51). The fact that such cases are being reported, albeit rarely, seems worrying. Again, we would therefore stress the need for making sure all homeopaths are medically competent.

We were unable to extract the data from one article that combined homeopathy with other modalities, such as herbals and dietary supplements. e.g. (52); in this retrospective analysis of cases, homeopathy had the second highest hospitalisation index with a total of 255 AEs reported.

Our systematic review has several strengths; we conducted extensive literature searches, did not impose restrictions according to language or time of publication, assessed the reported cases according to predefined criteria and tried to exclude bias where we could. We were able to include more AEs than any previous review has done. However, our systematic review also has a number of important limitations. They pertain to the potential incompleteness of the evidence. AEs of homeopathy are likely to be underreported; therefore, the number of cases summarised herein is less meaningful than the fact that such incidents exist at all. The often low quality of the primary reports further limits the conclusiveness of our findings. Several reports lacked sufficient detail, which renders the interpretation of their findings problematic (13,15,23,27,28,34,37,38,40). Given such caveats, a cause-effect relationship between the homeopathy and the AEs was frequently difficult to establish. We did not include systematic reviews, clinical trials, surveys and cohort studies in our review. A systematic review of the AEs of homeopathy, concluded that the incidence of AEs of homeopathic remedies was greater than that of placebo in controlled clinical trials; AEs included headache, tiredness, skin eruptions, dizziness, bowel dysfunctions and allergic reactions (53). Our review of CR and CS is thus not comprehensive. Crucially, it does not tell us anything about the incidence of AEs. Considering the widespread use of homeopathy worldwide and the relative paucity of the reported AEs, it might be very low. Collectively, these limitations render our review less conclusive than we had hoped.

In conclusion, several reports of AEs of homeopathy have been published and some AEs had serious consequences. Clinicians should be aware of the risks associated with homeopathy.

## Acknowledgements

PP has a fellowship from the Royal College of Physicians, London. The RCP had no role in study design, data collection and interpretation. PP would like to thank Professor Yori Gidron for his translation of the Hebrew article.

## Reference

- Ernst E, Pittler MH, Wider B, Boddy K. *The Desktop Guide to Complementary and Alternative Medicine*, 2nd edn. Edinburgh: Elsevier Mosby, 2006.
- Hunt K, Ernst E. Patients' use of CAM: results from the Health Survey for England 2005. *Focus Altern Complement Ther* 2010; **15**: 101–3.
- Ernst E. Risk-free homeopathy? *Schweiz Med Wochenschr* 1996; **126**: 1677–9.
- Vickers A, Zollman C. ABC of complementary medicine – homeopathy. *BMJ* 1999; **319**: 1115–8.
- Aberer W, Strohal R. Homeopathic preparations – severe adverse-effects, unproved benefits. *Dermatologica* 1991; **182**: 253.
- Audicana M, Bernedo N, Gonzalez I, Munoz D, Fernandez E, Gastaminza G. An unusual case of baboon syndrome due to mercury present in a homeopathic medicine. *Contact Dermatitis* 2001; **45**: 185.
- Aviner S, Berkovitch M, Dalkian H, Braunstein R, Lomnicki Y, Schlesinger M. Use of a homeopathic preparation for “infantile colic” and an apparent life-threatening event. *Pediatrics* 2010; **125**: E318–23.
- Barquero RJ, Redondo Lopez JM, Galeano DF, Perez MM. [Fatal acute pancreatitis in a patient

## Appendix:

### Detailed search strategy for medline

- (homeop\$ or homeop\$ or homoop\$).ti,ab,tw
- Exp Homeopathy
- (adrs or adr or complicat\$ or aggravat\$ or exacerbat\$).ti,ab
- (safe or safety or risk\$ or harm\$).ti,ab
- Side effect\$.ti,ab
- (Adverse ADJ3 (effect\$ or event\$ or interaction\$ or outcome\$ or reaction\$ or response\$)).ti,ab
- (Undesir\$ ADJ3 (effect\$ or event\$ or interaction\$ or outcome\$ or reaction\$ or response\$)).ti,ab
- (Unexpected ADJ3 (effect\$ or event\$ or interaction\$ or outcome\$ or reaction\$ or response\$)).ti,ab
- (Uninten\$ ADJ3 (effect\$ or event\$ or interaction\$ or outcome\$ or reaction\$ or response\$)).ti,ab
- (Unwanted ADJ3 (effect\$ or event\$ or interaction\$ or outcome\$ or reaction\$ or response\$)).ti,ab
- (Serious ADJ3 (effect\$ or event\$ or interaction\$ or outcome\$ or reaction\$ or response\$)).ti,ab
- (tolerate or tolerability or tolerance or tolerant or hypersensativ\$ or allerg\$).ti,ab
- (intolerate or intolerability or intolerance or intolerant).ti,ab
- (toxic\$ or toxin\$ or intox\$ or Poison\$ or noxious or septic\$ or hepatotoxic\$ or phototoxic\$ or nephrotoxic\$ or carcinogenic\$ or cardiotoxic\$ or cytotoxic\$ or Genotoxic\$).ti,ab
- (adulterat\$ or contaminat\$ or interact\$ or pollut\$).ti,ab
- (Death\$ or fatal\$).ti,ab
- (Overdose or Over-dose).ti,ab.
- Aftereffect\$.ti,ab
- Reaction\$.ti,ab
- secondary respons\$.ti,ab
- chemically induced.ti,ab
- Contraindication\$.ti,ab
- sequela\$.ti,ab
- (death ADJ3 sudden\$).ti,ab
- exp drug toxicity
- Exp postmarketing surveillance
- Exp Case Report\$
- (Case\$ Adj3 (stud\$ or report\$ or histor\$ or series\$ or record\$)).ti,ab
- 1 or 2 AND 3 or 4 or 5 or 6 or 7 or 8 or 9 or 10 or 11 or 12 or 13 or 14 or 15 or 16 or 17 or 18 or 19 or 20 or 21 or 22 or 23 or 24 or 25 or 26 or 27 or 28

- who received an homeopathic treatment]. [Spanish]. *Med Clin* 2004; **122**:318–9. Mar 6.
- 9 Benmeir P, Neuman A, Weinberg A et al. Giant melanoma of the inner thigh – a homeopathic life-threatening negligence. *Ann Plast Surg* 1991; **27**: 583–5.
  - 10 Bernez A, Perrinaud A, bdallah-Lotf M, Magro P, Machtet L. [DRESS syndrome with severe pulmonary involvement following oral intake of a homeopathic drug]. [French]. *Ann Dermatol Venereol* 2008; **135**:140–2.
  - 11 Cardinali C, Francalanci S, Giomi B, Caproni M, Sertoli A, Fabbri F. Contact dermatitis from *Rhus toxicodendron* in a homeopathic remedy. *J Am Acad Dermatol* 2004; **50**: 150–1.
  - 12 Chakraborti D, Mukherjee SC, Saha KC, Chowdhury UK, Rahman MM, Sengupta MK. Arsenic toxicity from homeopathic treatment. *J Toxicol Clin Toxicol* 2003; **41**: 963–7.
  - 13 Colin P. Homeopathy and respiratory allergies: a series of 147 cases. *Homeopathy* 2006; **95**: 68–72.
  - 14 Curry TB, Gaver R, White RD. Acquired long QT syndrome and elective anesthesia in children. *Pediatr Anesth* 2006; **16**: 471–8.
  - 15 Delaunay P. Homeopathy may not be effective in preventing malaria. *BMJ* 2000; **321**: 1288.
  - 16 Duque-Estrada B, Vincenzi C, Misciali C, Tosti A. Alopecia secondary to mesotherapy. *J Am Acad Dermatol* 2009; **61**: 707–9.
  - 17 Edelson G, Levy Y, Shoenfeld Y. Relapse of sarcoidosis after alternative medical treatment. *Harefuah* 1999; **136**: 849–50.
  - 18 Farrell J, Campbell E, Walshe JJ. Renal failure associated with alternative medical therapies. *Ren Fail* 1995; **17**: 759–64.
  - 19 Forsman S. Homeopati kan vara farliga vid hudsjukdomar och allergier. *Läkartidningen* 1991; **88**: 1672.
  - 20 Geukens A. Two more case histories. *J Am Ins Homeopath* 2001; **94**: 93–105.
  - 21 Goodyear H, Harper J. Atopic eczema, hyponatraemia, and hypoalbuminaemia. *Arch Dis Child* 1990; **65**: 231–2.
  - 22 Guha S, Dawn B, Dutta G, Chakraborty T, Pain S. Bradycardia, reversible panconduction defect and syncope following self-medication with a homeopathic medicine. *Cardiology* 1999; **91**: 268–71.
  - 23 Ibsen H, Halkier-Sorensen L, Thestrup-Pedersen K. Complications in patients with atopic dermatitis after use of an alternative treatment. *Ugeskr Laeger* 1987; **149**: 1246–7.
  - 24 Kerr HD, Yarborough GW. Pancreatitis following ingestion of a homeopathic preparation. *N Engl J Med* 1986; **314**: 1642–3.
  - 25 Kuenzli S, Grimaitre M, Krischer J, Saurat JH, Calza AM, Borradori L. Childhood bullous pemphigoid: report of a case with life-threatening course during homeopathy treatment. *Pediatr Dermatol* 2004; **21**: 160–3.
  - 26 Luder A, Frydman G. The mortality and morbidity of non-medical (“Alternative”) treatment for minors. *Int J Adolesc Med Health* 2000; **12**: 295–305.
  - 27 Menniti-Ippolito F, Mazzanti G, Santuccio C et al. Surveillance of suspected adverse reactions to natural health products in Italy. *Pharmacoepidemiol Drug Saf* 2008; **17**: 626–35.
  - 28 Monk B. Severe cutaneous reactions to alternative remedies. *BMJ* 1986; **293**: 665–6.
  - 29 Montoya-Cabrera MA, Rubio-Rodriguez S, Valazquez-Gonzalez E, Avila MS. Intoxicacion mercurial causada por un medicamento homeopatico. *Gaceta Med Mex* 1991; **127**: 267–70.
  - 30 Mortelmans LJM, Biesemans L, Van Rossom P. Homeopathic products, not as innocent and safe as they seem? A case report. *Eur J Emerg Med* 2004; **11**: 242–3.
  - 31 Potier JP. Bromate intoxication due to the ingestion of a dose prescribed by a homeopathist. *Nephrol Dial Transplant* 1998; **13**: 2978–9.
  - 32 Prasad HRY, Malhotra AK, Hanna N et al. Arsenicosis from homeopathic medicines: a growing concern. *Clin Exp Dermatol* 2006; **31**: 497–8.
  - 33 Rodriguez-Vico JS, Martinez-Pueyo A, Mendoza-Rodriguez A, Duarte J. Neurological manifestations in accidental poisoning by homeopathic kerosene. *Neurologia* 2009; **24**: 432–3.
  - 34 Sasseville D, Nguyen K. Allergic contact dermatitis from *Rhus toxicodendron* in a phytotherapeutic preparation. *Contact Dermatitis* 1995; **32**: 182–3.
  - 35 Stevens W. Thallium intoxication caused by a homeopathic preparation. *Toxicol Eur Res* 1978; **1**: 317–20.
  - 36 Turkoglu-Rauch G, Grone HJ, Sitter T, Fischereder M. Another “suspect”: homeopathic agent associated with acute interstitial nephritis. *Dtsch Med Wochenschr* 2010; **135**: 1224–7.
  - 37 Van Ulsen J, Stolz E, Joost T. Chromate dermatitis from a homeopathic drug. *Contact Derm* 1988; **18**: 56–7.
  - 38 von Mach MA, Habermehl P, Zepp F, Weilemann LS. Drug poisonings in childhood at a regional poisons unit. *Klin Padiatr* 2006; **218**: 31–3.
  - 39 Wille D, Hauri-Hohl M, Vonbach P, Tomaske M, Padden B, Bernet V. Too much of too little: xylitol, an unusual trigger of a chronic metabolic hyperchloremic acidosis. *Eur J Pediatr* 2010; **169**: 1549–51.
  - 40 Zuzak TJ, Rauber-Luthy C, Simoes-Wust AP. Accidental intakes of remedies from complementary and alternative medicine in children-analysis of data from the Swiss Toxicological Information Centre. *Eur J Pediatr* 2010; **169**: 681–8.
  - 41 Lim A, Cranswick N, South M. Adverse events associated with the use of complementary and alternative medicine in children. *Arch Dis Child* 2011; **96**: 297–300.
  - 42 [http://www.homeopathy-soh.org/attachments/2011/04/ECCHSafetyReport\\_2009.pdf](http://www.homeopathy-soh.org/attachments/2011/04/ECCHSafetyReport_2009.pdf) (accessed April 2012). 2012.
  - 43 Thompson E, Barron S, Spence D. A preliminary audit investigating remedy reactions including adverse events in routine homeopathic practice. *Homeopathy* 2004; **93**: 203–9.
  - 44 Grabia S, Ernst E. Homeopathic aggravations: a systematic review of randomised, placebo-controlled clinical trials. *Homeopathy* 2003; **92**: 92–8.
  - 45 Forth W. Potentiell toxische Schwermetalle als Therapeutikum in der Homöopathie. *Deutsches Ärzteblatt* 1996; **93**: 1653–4.
  - 46 Tsur M. Inadvertent child health neglect by preference of homeopathy to conventional medicine. *Harefuah* 1992; **122**: 137–42.
  - 47 Pilkington K, Kirkwood G, Rampes H, Fisher P, Richardson J. Homeopathy for anxiety and anxiety disorders: a systematic review of the research. *Homeopathy* 2006; **95**: 151–62.
  - 48 Pilkington K, Kirkwood G, Rampes H, Fisher P, Richardson J. Homeopathy for depression: a systematic review of the research evidence. *Homeopathy* 2005; **94**: 153–63.
  - 49 Ernst E. Homeopathy for eczema: a systematic review of controlled clinical trials. *Br J Dermatol* 2012; **166**: 1170–2.
  - 50 Cooper KL, Relton C. Homeopathy for insomnia: a systematic review of research evidence. *Sleep Med Rev* 2010; **14**: 329–37.
  - 51 Ernst E. A systematic review of systematic reviews of homeopathy. *Br J Clin Pharmacol* 2002; **54**: 577–82.
  - 52 Vassilev ZP, Chu AF, Ruck B, Adams EH, Marcus SM. Evaluation of adverse drug reactions reported to a poison control center between 2000 and 2007. *Am J Health-Syst Pharm* 2009; **66**: 481–7.
  - 53 Dantas F, Rampes H. Do homeopathic medicines provoke adverse effects? A systematic review. *Br Homeopath J* 2000; **89** (Suppl. I): S35–8.

Paper received May 2012, accepted August 2012